Skull (Internal Aspect)
Foramina and Their Conveyances
v002

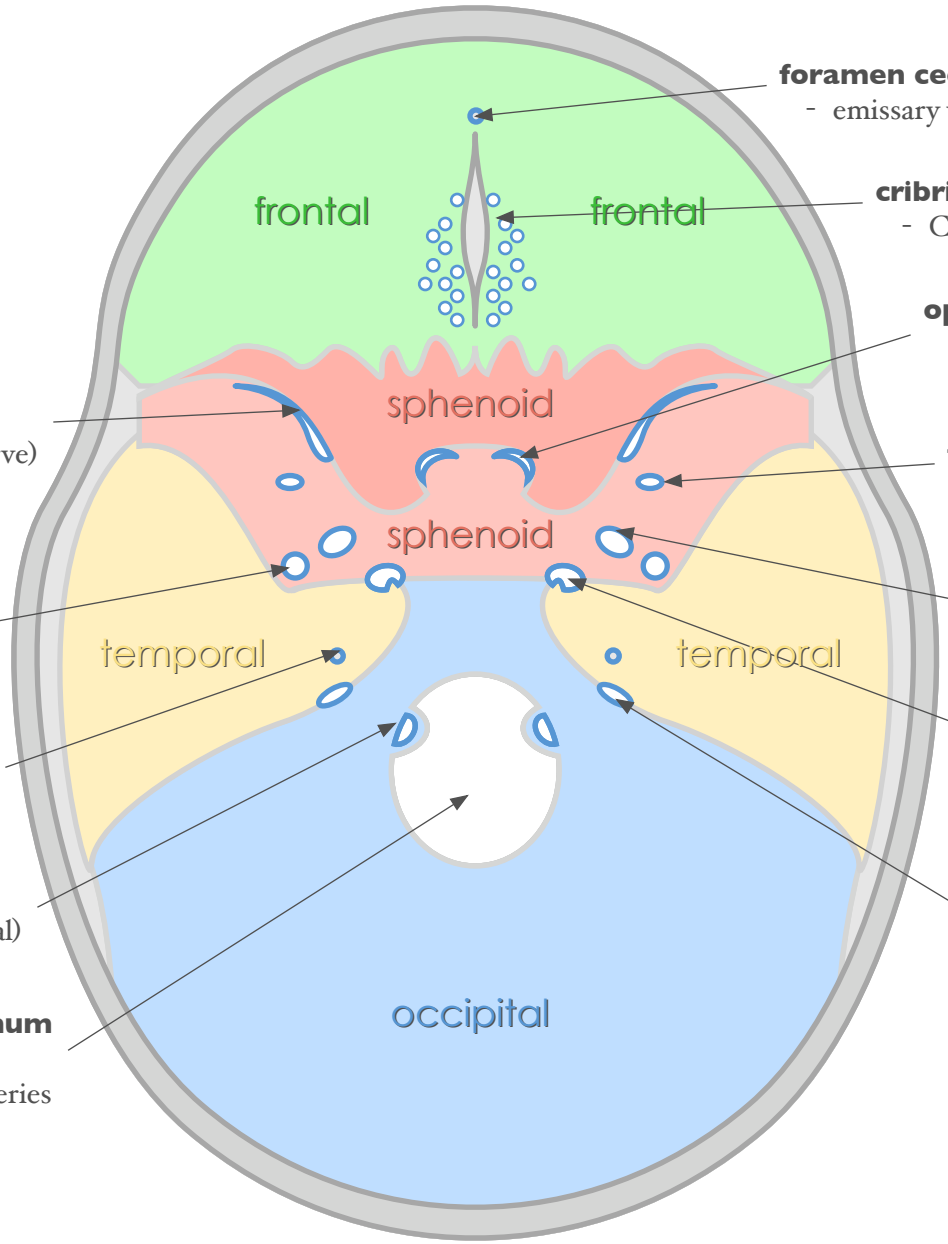

foramen cecum
- emissary veins to superior sagittal sinus

cribriform plate
- CN I (olfactory)

optic canal
- CN II (optic)
- ophthalmic artery

foramen rotundum
- CN V_2 (trigeminal / maxillary nerve)

foramen ovale
- CN V_3 (trigeminal / mandibular nerve)

foramen lacerum
- internal carotid artery

jugular foramen
- internal jugular vein
- CN IX (glossopharyngeal)
- CN X (vagus)
- CN XI (accessory)

superior orbital fissure
- CN III (oculomotor)
- CN IV (trochlear)
- CN V_1 (trigeminal / ophthalmic nerve)
- CN VI (abducens)
- superior ophthalmic vein

foramen spinosum
- middle menigeal artery

internal acoustic meatus
- CN VII (facial)
- CN VIII (vestibulocochlear)

hypoglossal canal
- CN XII (hypoglossal)

foramen magnum
- spinal cord
- vertebral arteries

Kyle Rove, M '09
Georgetown School of Medicine
kor3@georgetown.edu